

KaVo RONDOflex Plus 360.

All around solution for minimal invasive cavity preparation.



The Air-Abrasion-System with additional water supply and reduced powder contamination.
Dr Michael N. Mandikos on his experiences with the KaVo RONDOflex Plus 360.



Dr Michael N. Mandikos

Prosthodontist

Dr Mandikos is a Visiting Specialist to the University of Queensland Dental School and formerly a Specialist Consultant to the Royal Australian Air Force. He is a Reviewer for several international Dental Journals and a product evaluator for several dental companies. Dr Mandikos regularly presents continuing dental education programs throughout Australia and South-East Asia, and is in Specialist private practice in Brisbane, Australia.

Vita

- 1992 – Graduated with Honours, from University of Queensland, Australia
- 1998 – Certificate in Prosthodontics State University of New York at Buffalo
- 1998 – Master of Science (Biomaterials) State University of New York at Buffalo
- 2000 – Fellow Royal Australasian College of Dental Surgeons

Affiliation

- Visiting Specialist, University of Queensland
- Member of Australian Dental Association
- Member of Australian and New Zealand Academy of Prosthodontists
- Member of Australian Prosthodontic Society
- Member of Australian Osseointegration Society

Dr Michael N. Mandikos

Suite 5 | 158 Graceville Avenue | Graceville |
Queensland 4075 | Australia

michael@brisbaneprosthodontics.com.au

Whilst air abrasion is clinically very effective and rising in popularity...

Air abrasion, sometimes referred to as sandblasting, involves treating the surface of the tooth or dental restoration with a fine spray of aluminium oxide particles. It is well documented as a method to increase the retentiveness of the treated surface for subsequent adhesive procedures^{1,2}. The process involves the controlled pressure delivery of microscopic aluminium oxide particles (usually between 30 µm to 50 µm) to the tooth or restoration surface. The air abraded surface is indented by the harder alumina particles, leading to a microretentive roughened and higher energy surface, ready for bonding. The technique is especially suited for pretreating dentine, metal or ceramic surfaces before resin based adhesives and cements are then applied. Air abrasion can also be used on enamel surfaces as well, with many reports in the Orthodontic literature suggesting that the bond

strength of orthodontic brackets to air abraded enamel is greater than for acid etching alone³. Air abrasion may also increase the bond strength of self etching dentine bonding systems to dentine, by removing the smear layer prior to the adhesive being applied⁴.

Whilst air abrasion is clinically very effective and rising in popularity with clinicians who work with advanced bonding situations, one of its major drawbacks has been the mess associated with the procedure. Intraoral air abrasion results in the scattering of the used microscopic alumina particles throughout the mouth, as well as out and onto the patient's face, and often all over the immediate clinical working environment. This can include the Dentist's gloves, the floor and even the working benchtops in the clinical setting.



KaVo RONDOflex™ 360

The pressure-sprayed alumina particles are well contained within the water spray and are not scattered throughout the mouth or clinical working space.



Corundum powder for KaVo RONDOflex™ 360, 27 µm grade for lower abrasive power.

These particles are not only a nuisance to the clinician, but they also can remain in the mouth after copious irrigation and the patient rinsing, and can possibly settle onto the tooth surface immediately prior to the seating of the definitive restoration. The particles thus are at risk of becoming incorporated in the final cement film. The potential for contaminating the cement in this way, together with the general mess that air abrasion with alumina particles can often make, has dissuaded some clinicians from taking up this form of surface treatment prior to bonding procedures.

Fortuitously, Kavo Kerr provided a solution to the problem of air abrasion mess when they introduced the RONDOflex 360 Air Abrasion System in 2007. The RONDOflex 360 provides its stream of alumina particles within the confines of a concurrent water spray, not dissimilar to the way a dental handpiece

releases a water spray around its dental bur. In fact, the RONDOflex 360 connects to the same coupling that an air turbine high-speed handpiece connects to, which further enhances the convenience of the device, as it does not require separate or additional couplings to be fitted to the Clinician's bracket table. Thus, the RONDOflex 360 can effect the air abrasion of a tooth surface intraorally, within the confines of what appears to be a simple water spray directed onto the tooth. As a result, the pressure-sprayed alumina particles are well contained within the water spray and are not scattered throughout the mouth or clinical working space. The RONDOflex 360 allows the Clinician to cleanly pre-treat the tooth surface or intaglio surface of the restoration (if held over a sink or other receptacle to catch the water) without the mess that is typically associated with the air abrasion process.

The following case report demonstrates the use of the RONDOflex 360 for enhancing and optimizing the adhesion between the restoration and tooth, in a complex clinical situation.

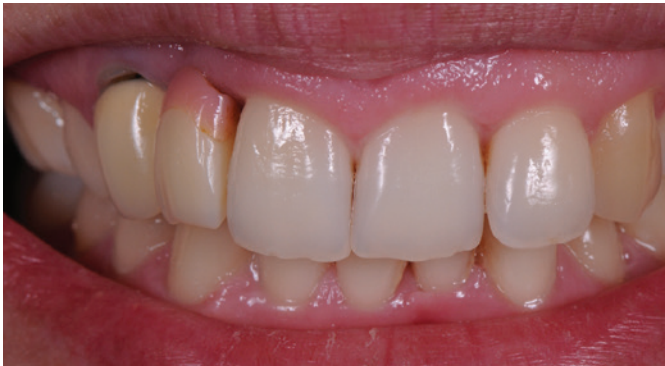

Figure 1

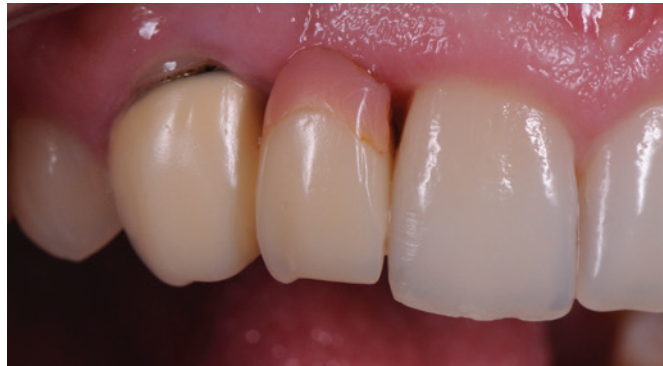

Figure 2

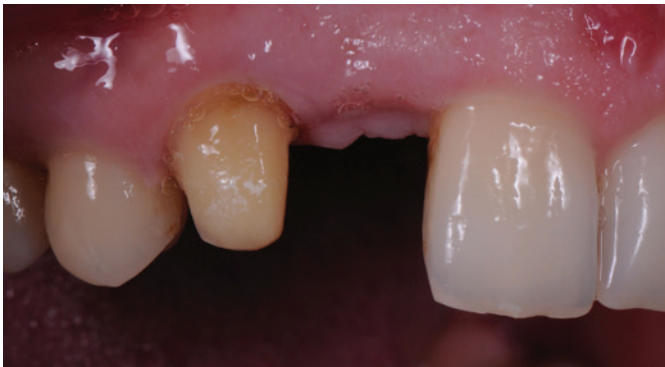

Figure 3

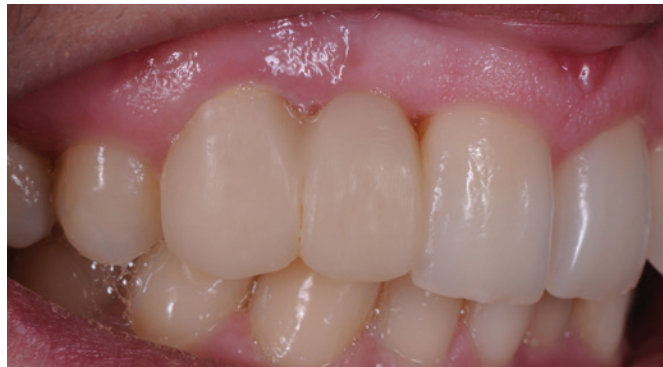

Figure 4

Figures 1 & 2: The patient was a young lady who was previously treated for the congenital absence of a maxillary right lateral incisor with a two-unit cantilever bridge. Whilst the canine is a very capable abutment tooth for such a treatment option, it was unfortunate that the tooth had been prepared for a full coverage retainer, rather than treated with a palatally bonded retainer for a Maryland-style, bonded bridge. The patient was unhappy with the aesthetic appearance of the existing prosthesis and sought a replacement option.

Figures 3 & 4: After discussion with the patient and obtaining consent, it was decided that the treatment would involve replacement of the bridge, without soft tissue augmentation of the residual ridge. The existing bridge was thus removed, the existing heavy preparation of the abutment tooth was refined, impressions and records were made, and then a provisional bridge was placed.

Figures 5 & 6: The Ceramist then fabricated the definitive bridge using a lithium disilicate frame (eMax) layered with eMax Ceram, to achieve the final aesthetic result. The design was a two-unit cantilever, similar to the previous prosthesis, but with an emphasis on connector dimension for strength of the final restoration.

Figure 7: At the time of bridge placement, it was decided that an enhanced adhesion protocol was required due to the overly short and tapered nature of the abutment tooth preparation, and the additional loads that would be applied by the cantilever design of the bridge. The clinical situation thus indicated that the abutment tooth should be air abraded with alumina particles, to improve the quality of the final bond. The tooth substrate was isolated with retraction cord and the cantilever bridge was then tried in and adjustments made to perfect the fit.

Figure 8: Once the try-in and adjustment process was complete, the abutment tooth was cleanly air abraded with the RONDOflex 360.

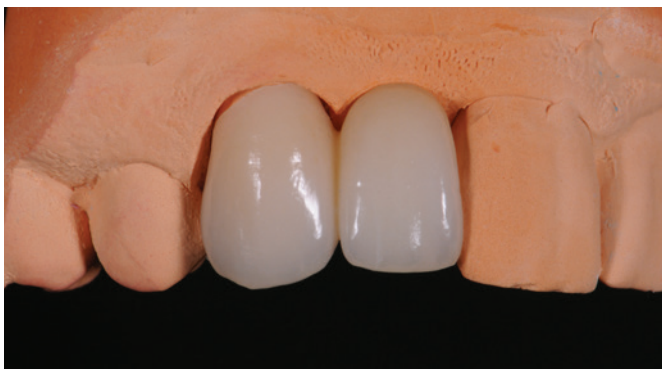

Figure 5

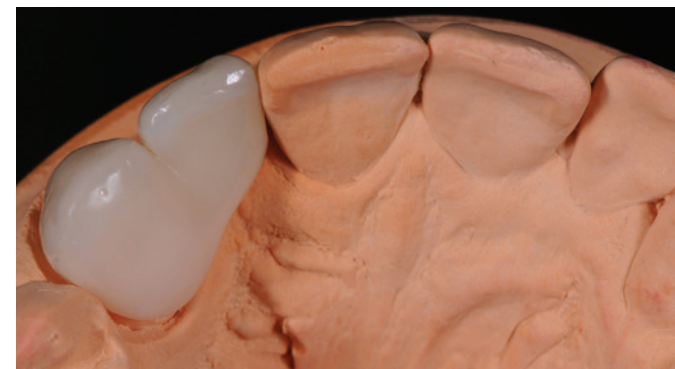


Figure 6

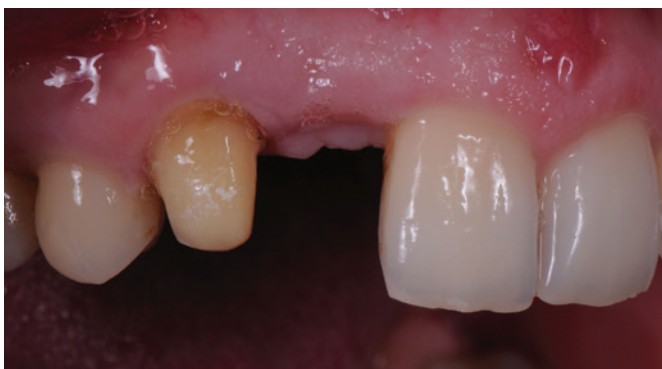

Figure 7

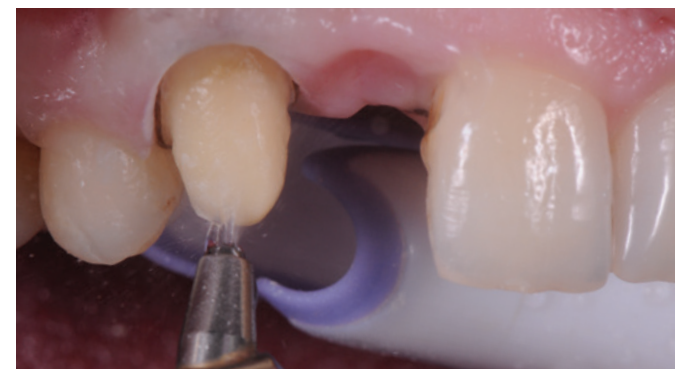

Figure 8

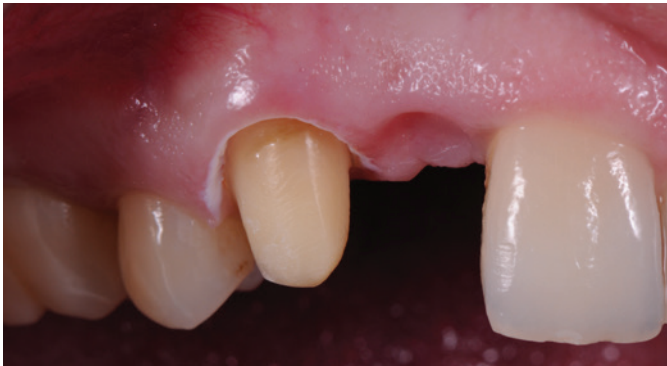

Figure 9

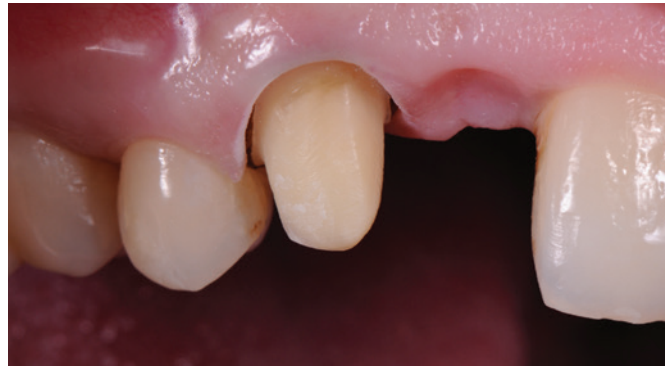

Figure 10

Figure 9 & 10: The appearance of the dentine surface is observed to change from a slightly glossy finish to a more matt appearance after the use of the RONDOflex 360. This indicates the successful application of air abrasion and the establishment of a micro-roughened surface, ready for subsequent bonding procedures.

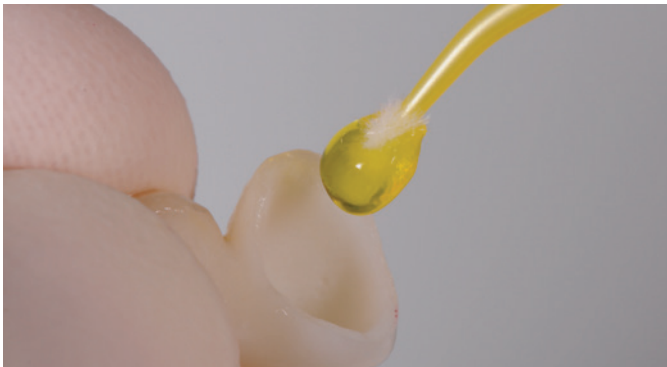

Figure 11

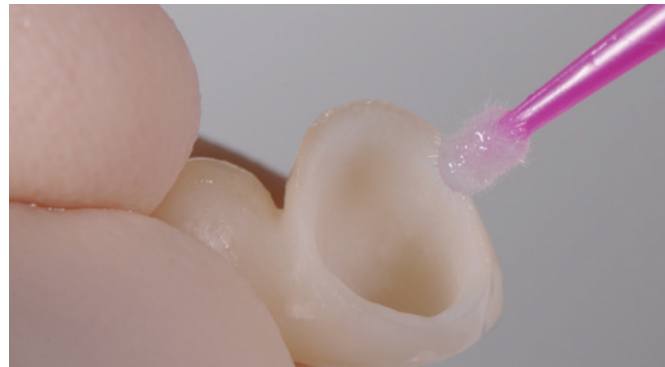

Figure 12

Figures 11 & 12: After the tooth was air abraded, the internal surface of the lithium disilicate (eMax) bridge was treated with Hydrofluoric acid etching and then a silane was applied, to optimize the bonding.

Figure 13: The tooth surface was then treated with Optibond XTR as the dentine adhesive. The adhesive was applied according to the manufacturer's instructions but not light cured until the bridge was seated. The bridge was loaded with Kerr's NX3 resin veneer cement, and light curing was effected to concurrently cure the adhesive and the cement.

Figure 14: Upon successful cleanup of the residual cement, the occlusion was again checked (to ensure excursion only on the canine and no guidance provided from the pontic) and the patient was asked to return one month later for the final case review.

Figures 15 & 16: The patient returned one month later for her final case review. Her ability to maintain and clean the prosthesis was perfect, her bite was even and the guidance was in harmony with the rest of her mouth. The clinical outcome was quite ideal, and the patient was very pleased with the aesthetic and functional outcome with her new bridge.

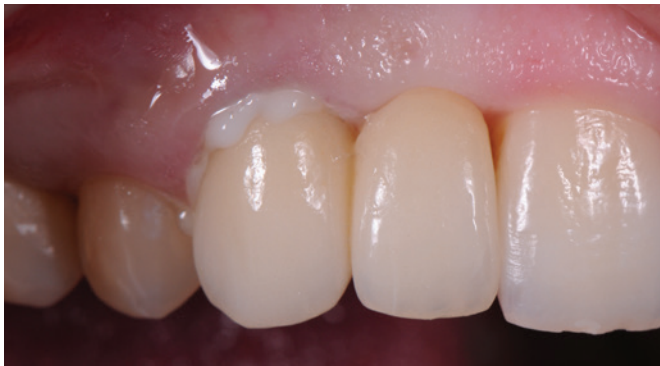

Figure 13

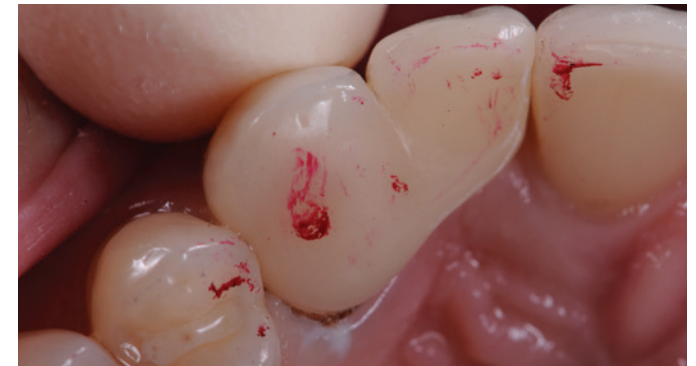

Figure 14

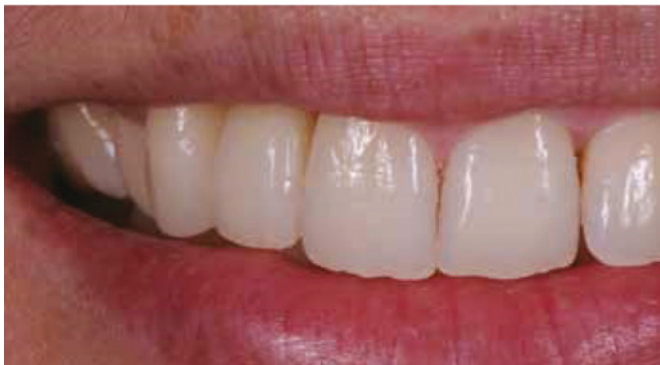

Figure 15

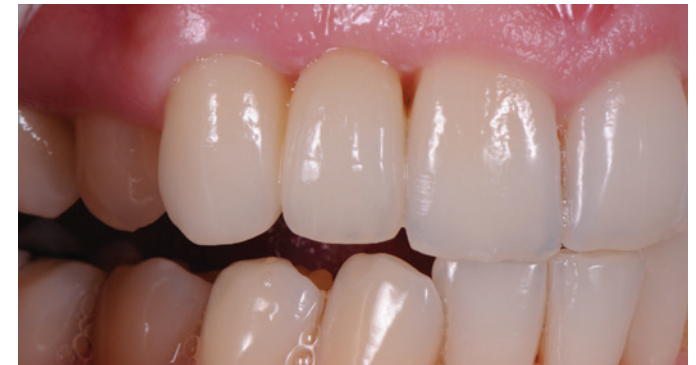

Figure 16

References:

1. Coli P, Alaeddin S, Wennerberg A & Karlsson S. In vitro dentin pretreatment: Surface roughness and adhesive shear bond strength. *European Journal of Oral Science* 1999. 107(5): 400-413.
2. Hanning M & Femerling T. Influence of air-abrasion treatment on the interfacial bond between composite and dentin. *Operative Dentistry*. 1998. 23(5): 258-265.
3. Cal-Neto JP, Castro S, Moura PM, Ribeiro D, Miguel JA. Influence of enamel sandblasting prior to etching on shear bond strength of indirectly bonded lingual appliances. *Angle Orthod*. 2011. 81(1):149-52.
4. Chaves P, Giannini M & Ambrosano GM. Influence of smear layer pretreatments on bond strength to dentin. *Journal of Adhesive Dentistry* 2002. 4(3): 191-196.

Get more information at
www.kavo.com/dental-instruments/rondoflex-plus-360-special-instruments

The products, features and services shown and described in this catalogue are not available in all countries. All specifications were correct at the time of publication. KaVo Dental GmbH assumes no liability for deviations in colour or form from the illustrations, mistakes or printing errors and reserves the right to make changes to the brochures at any time.

KaVo™ and RONDOflex™ are either registered trademarks or trademarks of KaVo Dental GmbH in the United States and/or other countries. All other trademarks are property of their respective owners.

KaVo Dental GmbH | Bismarckring 39 | 88400 Biberach | Germany
www.kavo.com

KAVO
Dental Excellence